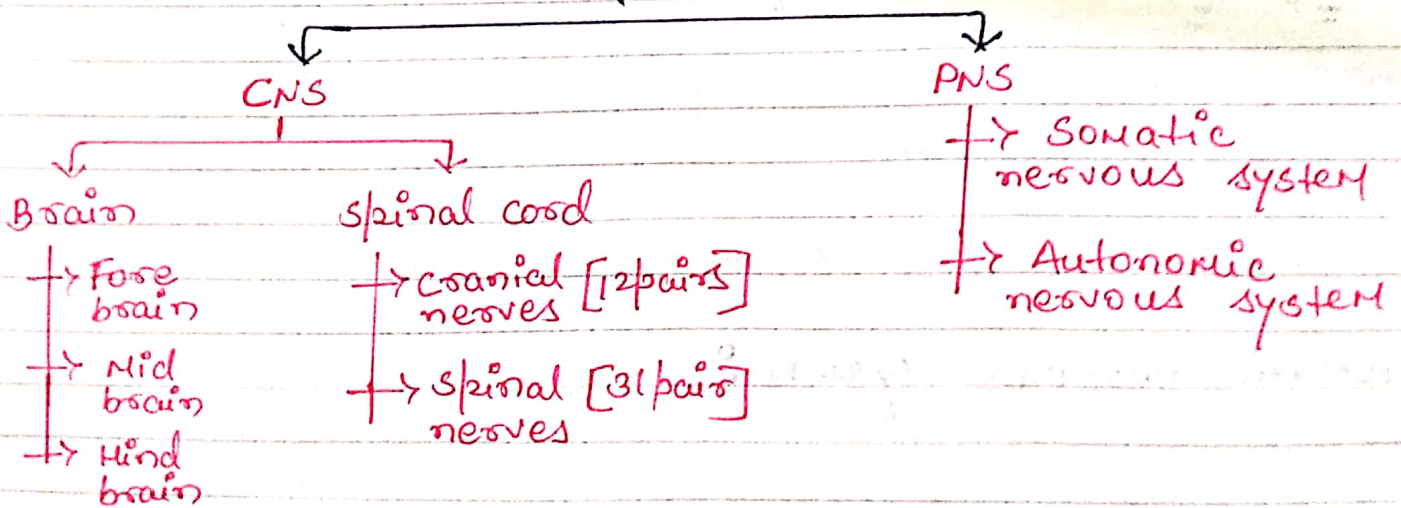


UNIT  $\Rightarrow$  I  
NERVOUS SYSTEM

# Organisation Of Nervous System

- Nervous system is the chief controlling and coordinating system of the body.
- The nervous system is one of the smallest system in the 11 body system but they control the other 10 body system.
- The nervous system have 3 main function
  - i) sensory - responsible for sense
  - ii) Intergative - analyse
  - iii) Motor - response action

NERVOUS SYSTEM



- NOTE :
- Brain which occupies cranial cavity.
  - Spinal cord which occupies vertebral canal.

## Peripheral nervous system:

- The peripheral nervous system consists of all nerves outside the brain & spinal cord.
- Peripheral nervous system includes:

### i) Somatic nervous system:

- For voluntary action
- The SNS consists of sensory neurons that conduct impulses from somatic & special sense receptors to the CNS & motor neurons from the CNS to skeletal muscle.

### ii) Autonomic nervous system:

- For involuntary action
- The ANS contains sensory neurons from motor neurons that convey impulses from CNS to smooth muscle tissue, cardiac muscle tissue, and glands.

# Nervous system consists of two specific type of cell:

(I) Neuroglia.

(II) Neurons.

-> Neuroglia cells:

• It is non neural cells (It is not a part of neuron or doesn't make neuron structure). It is present near neurons in CNS or PNS.

• It maintains Homeostasis.

• It helps to form myelin sheath.

• It provide support to neurons

• It provide protection to neuron

function of neuroglia cells:

- To <sup>surrounds</sup> ~~support~~ neurons & hold them in place.
- To supply nutrients & oxygen to neurons.
- To destroy pathogen & remove dead neurons.

Types of neuroglia cells: - total six types

i) Astrocytes

ii) Ependymal cells

iii) Oligodendrocytes cells

iv) Microglia

} these four cells are present in CNS

v) satellite cells

vi) Schwann cells

} these two cells are present in PNS.

## # Neurons

- [Each neuron consists of a cell body, one axon and many dendrites].
- Neurons are commonly referred to as nerve cells, because they are highly specialised cells of nervous system which can detect, receive and transmit different kinds of stimuli.
  - Neurons possess electrical excitability (the ability to respond to a stimulus and convert it into an action potential).

Note: - Stimulus: a stimulus is any change in the environment that is internally or externally in our body.

- Action potential (nerve impulse): Action potential is an electrical signal that propagates (travels) along the surface of the membrane of a neuron.

### → Parts of Neurons

- Each neuron consists of
  1. cell body
  2. Dendrites
  3. Axon
- Myelin sheath: It is outer covering of axon.
- when the M.S. is damaged known as sclerosis.
- Nodes of Ranvier: This is a region where no myelin sheath is present.
- It is also known as non-myelinated ~~nerve~~ ~~sheath~~

## Cell Body

- It contains nucleus surrounded by cytoplasm that includes lysosome, mitochondria & golgi complex.
- The other characteristics of neurons, <sup>cell body</sup> are neurofibril, nissl bodies, microtubules.
- Neurofibril: is the cytoskeleton of neuron which provide support & shape of body.
- microtubules: is also cytoskeleton of neuron which assist in moving material between the cell body & axon.

## Dendrites

- Nissl bodies: cell bodies contains ribosomes & prominent clusters of RER (rough endoplasmic reticulum) termed as nissl bodies.

## Dendrites

- Dendrites are the receiving or input portion of a neuron.
- The plasma membrane of dendrites contains numerous receptors site for binding chemical messenger from other cell.

- Dendrites usually are short, tapering & highly branched.

- Their cytoplasm contains nissle bodies, mitochondria & other organelles.

→ Axon :

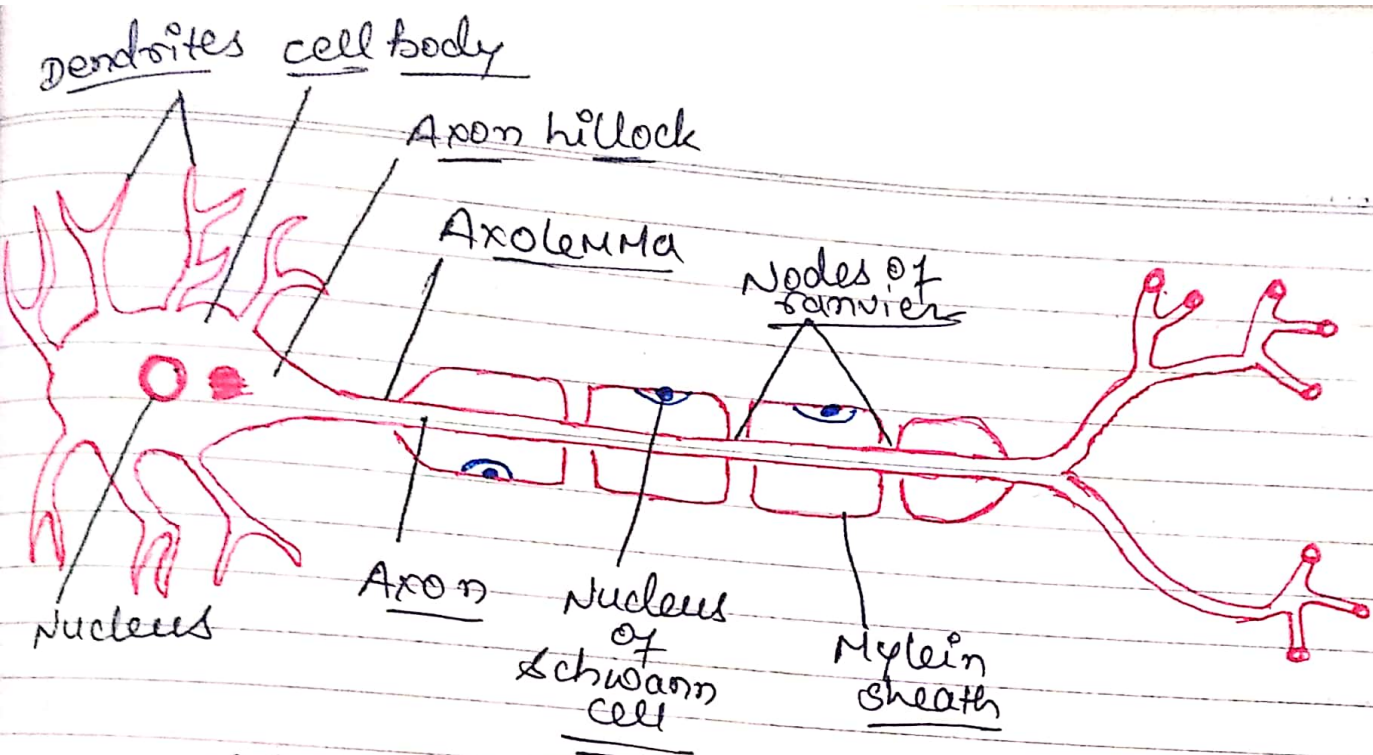
- The single axon of a neuron propagates nerve impulses towards ~~other~~ another neuron, a muscle fibre or a gland cell.

- Axon is a long, cylindrical projection that joins to the cell body at a cone-shaped structure called Axon Hillock.

- An axon contains mitochondria, microtubules & neurofibrils.

- Due to absence of rough endoplasmic reticulum ~~is not~~ ~~pro~~, protein synthesis doesn't occur in the axon.

- The cytoplasm of Axon is surrounded by a plasma membrane known as axolemma.



Classification of

## \* Classification of Neuron

• It is classified in 3 types (Neuron)

- i) unipolar
- ii) Bipolar
- iii) Multipolar

### unipolar

They have just one process extending from cell body

• There is a single process drites.

### → Bipolar

• There are two direct projections of dendrites

### → Multipolar

• There are several projections of dendrites.

• These are mostly located in brain & spinal cord.

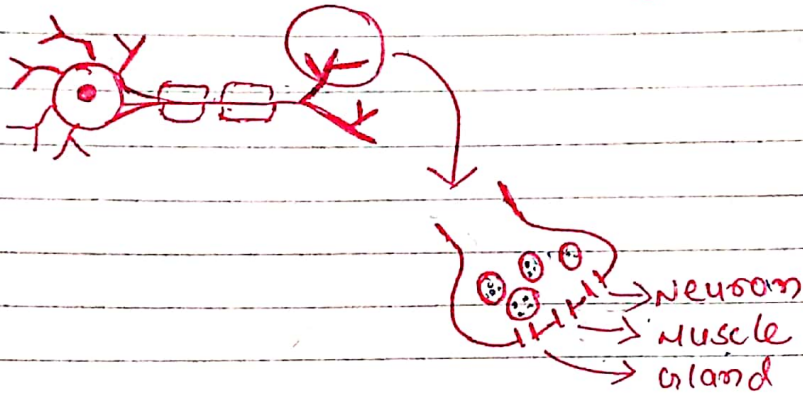
### → function of Neuron

- i) sensory
- ii) motor



## NEUROTRANSMITTER

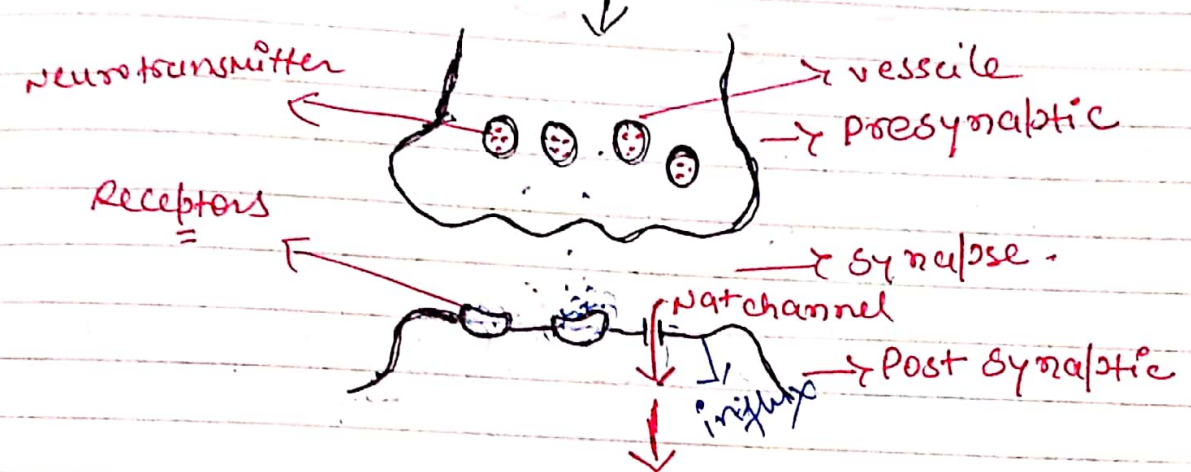
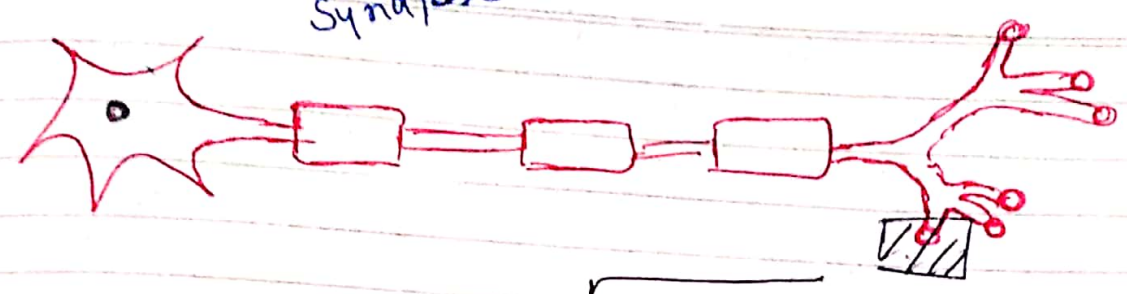

- Neurotransmitters are also called chemical transmitter or chemical messenger are released by neurons (nerve cells) to stimulate other neurons or muscle or gland cell.



- neurotransmitter may be either excitatory or inhibitory.

### # Excitatory neurotransmitter

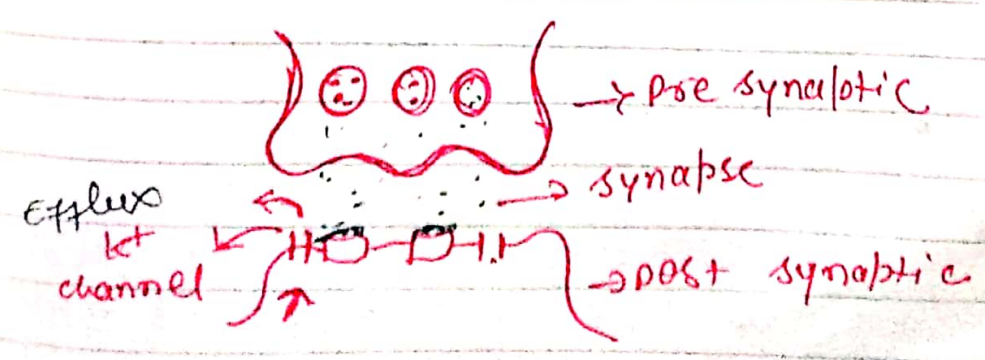
- It is the chemical substances which is responsible for the conduction of impulses from presynaptic neurons to post synaptic neurons.
- Normally the neurotransmitter is released from vesicle & move to the post synaptic receptor by passing synapse & generate an action potential but the excitatory neurotransmitter are doesn't generate action potential directly, after attach the receptors of post synapse. due to the attachment of excitatory neurotransmitter in post synapse  $Na^+$  channel is open.



• so then start following the Na<sup>+</sup> ions from outside to inside & this outside to inside flow of Na<sup>+</sup> ion known as influx of Na<sup>+</sup> ion. & due to this flowing a potential is generate called excitatory post synaptic potential (EPSP).

- After the impulse ~~pass~~ generate they goes & perform their physiological function.

### # Inhibitory neurotransmitter



- It is the chemical substance which inhibits the conduction of impulses from the presynaptic neuron to the post synaptic neuron.
- When neurotransmitter are released from the presynaptic due to ~~presence~~ <sup>arrival</sup> of action potential, it causes opening of  $K^+$  ion channel & the movement of  $K^+$  ion from inside to outside & it is known as efflux of  $K^+$  ion.
- This leads to hyperpolarization which is called inhibitory post synaptic potential & then action potential is not generated.

## ## Examples of neurotransmitter

### ① ADRENALINE :

- Adrenaline is primary a hormone released by the adrenal gland, but some neurons may secrete it as neurotransmitter.
- It increases heart rate and blood flow
- It is produced during stressful or exciting situations.

### ② DOPAMINE :

- It is primary responsible for feeling of pleasures, but it is also involved in movement & motivation.

- People tend to repeat behaviour that leads to addiction.

### ③ ACETACHOLINE ♂

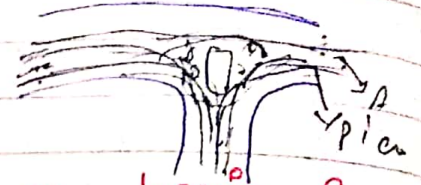
- Involved in thought, learning & memory within the brain.
- Activates muscle contraction in the body.

### ④ SEROTONIN ♂

- In the brain, it acts as inhibitory neurotransmitter that regulates mood, fears, feeling of relaxation, mental focus.
- In the gut, it acts as hormonal messenger that regulates digestion, nutrition absorption.

# Central Nervous System

## Meninges



- Meninges are protective covering of brain & spinal cord (CNS).
- Meninges contains three layers:
  - i) Outer layer called dura mater
  - ii) middle layer called arachnoid mater
  - iii) inner most layer called pia mater.
- The dura mater and arachnoid mater are separated by subdural space.
- The ~~areh~~ arachnoid & pia mater are separated by subarachnoid space containing cerebrospinal fluid.

## [I] Dura mater :

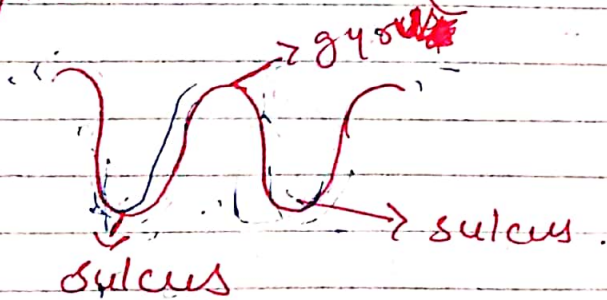
- The dura mater is double-layered called endosteal layer & meningeal layer.
- The endosteal layer is ~~attach~~ <sup>covers</sup> to the inner surface of skull
- The meningeal layer is outer covering of brain & continue as the dura mater of the spinal cord.

## (II) Arachnoid Mater :

- This is a layer of fibrous tissue.
- It contains collagen helps in shock absorption.
- The ~~subdural~~ subarachnoid space (inside the arachnoid) contains blood vessels & cerebrospinal fluid (CSF).

## (III) Pia Mater :

- The pia mater tightly covers the brain & spinal cord.
- Pia mater is bound to the surface of astrocytes in brain (in each sulcus & gyri).



→ [Gyrus is a single unit of gyri].

## ## Ventricles of brain & cerebrospinal fluid

- The brain contains four irregular-shaped cavities or ventricles containing CSF fluid.

- i) right & left lateral ventricles.
- ii) third ventricle
- iii) fourth ventricle.

### [I] The lateral ventricles:

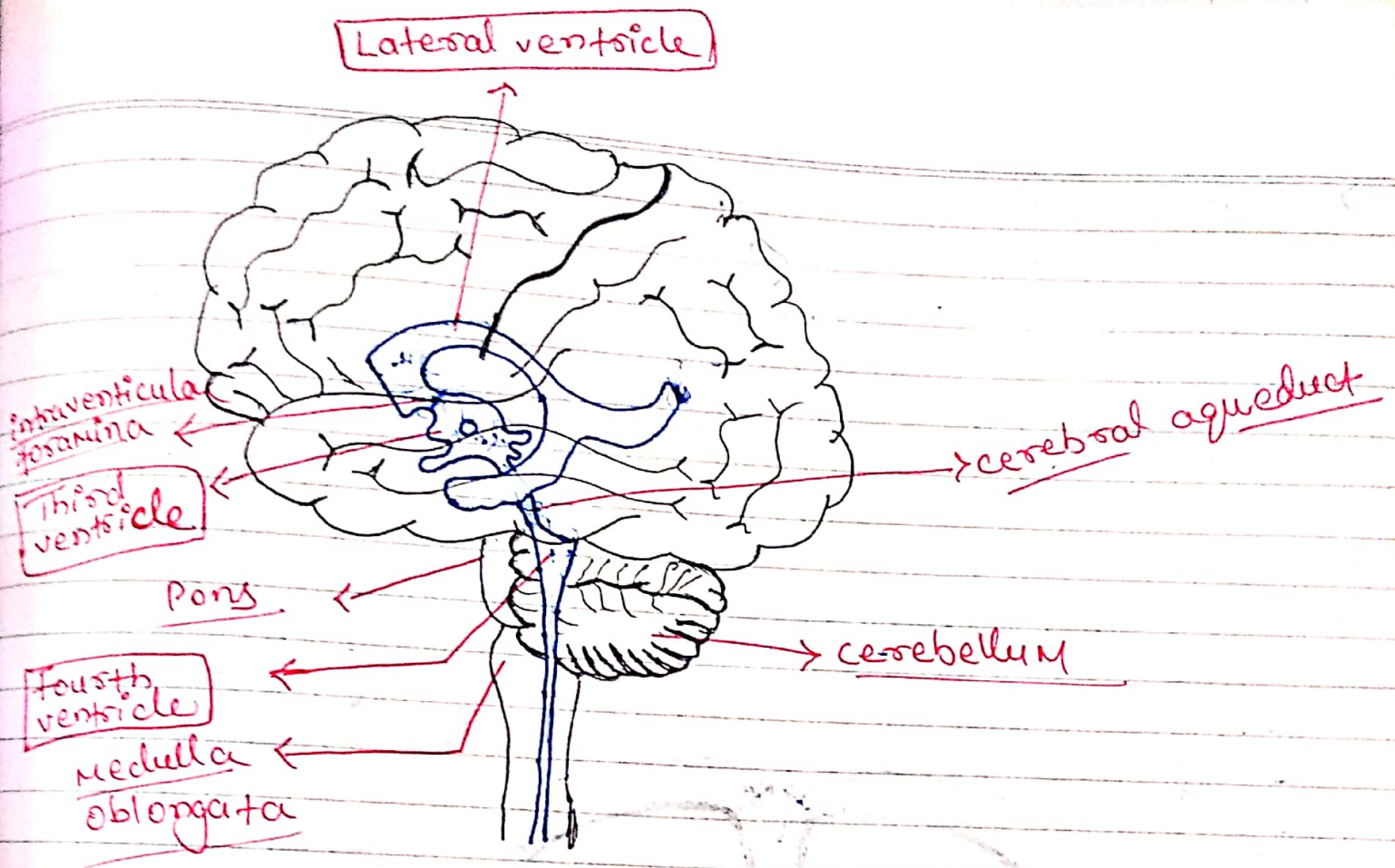
- These are lie within the cerebral hemisphere, one on each side of the median plane just below the corpus callosum.
- They are separated from each other by a thin membrane called septum lucidum.
- These ventricles communicate with third ventricle by interventricular foramina.

### [II] Third ventricle:

- It is a cavity situated below the lateral ventricle.
- It is communicate with fourth ventricle by a canal called cerebral aqueduct.

### [III] Fourth ventricle:

- It is diamond shaped cavity.
- It is situated below & behind the third ventricle between the cerebellum & pons.



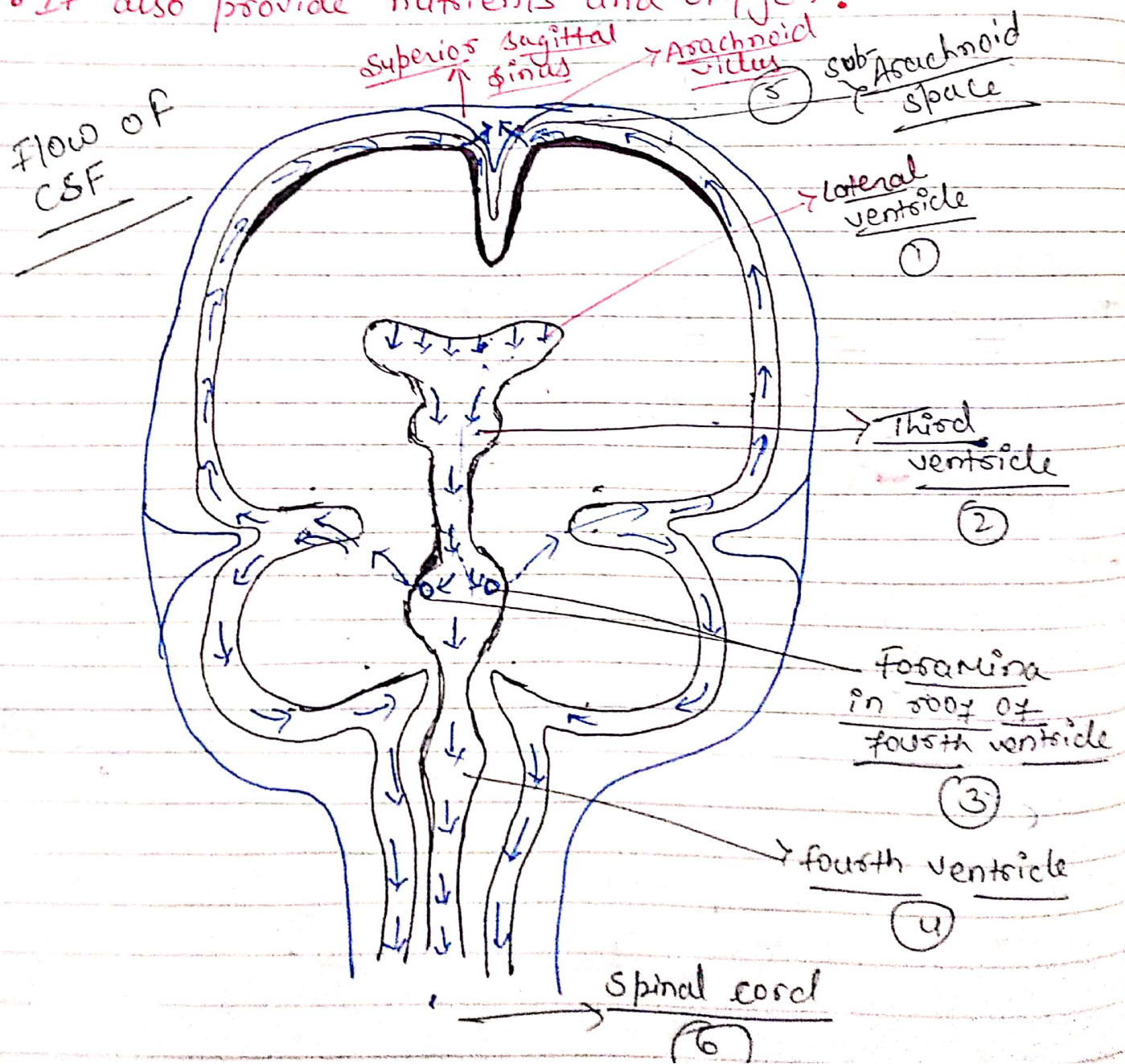
## # Cerebrospinal fluid (CSF) :

- CSF is a thick liquid it is clear alkaline fluid secreted into each ventricles of brain by choroid plexuses.
- The composition of CSF consist of water, mineral salt, glucose, plasma protein & few leucocytes.
- The CSF continuously secretes at rate of 0.5 ml/min i.e., 720 ml/day.
- The CSF pressure measured by using a ventricle tube attach to lumbar puncture needle.

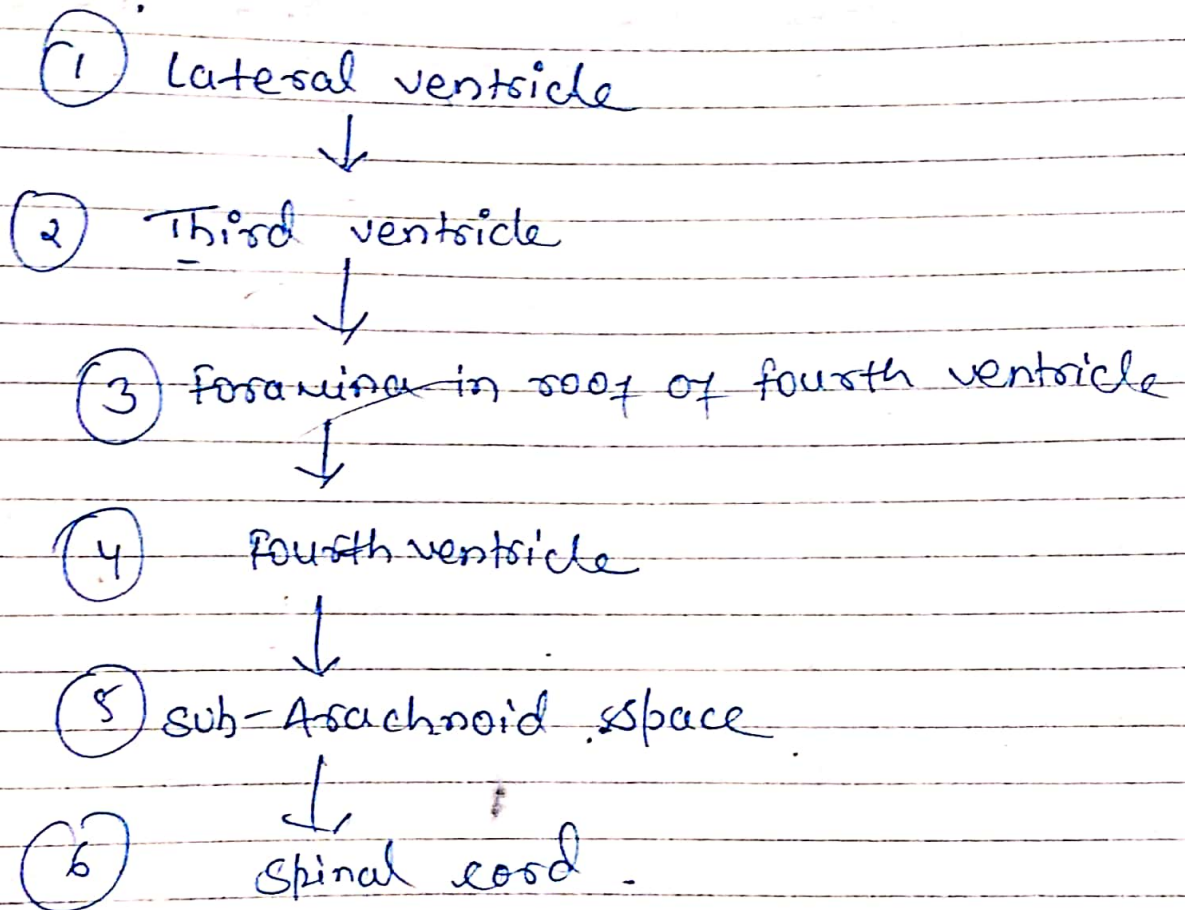


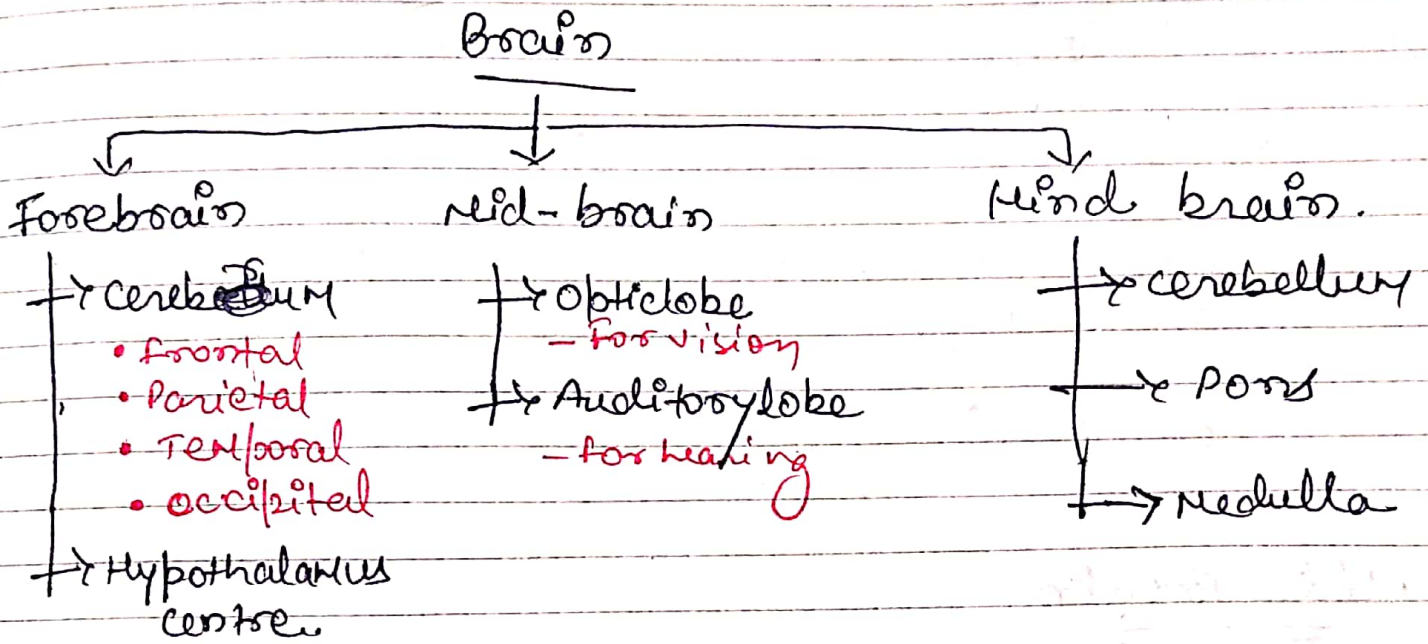
→ Function of CSF

- It supports & protect the brain & spinal cord.
- It acts as shock absorber b/w brain & the skull.
- It keeps the brain & spinal cord moist.
- It also provide nutrients and oxygen.



## flow chart of CSF





\* Hypothalamus centre

- It is composed of number of cells & situated below & in front of thalamus, immediately above the pituitary gland.
- It is linked to the posterior lobe of the pituitary gland by nerve fibres & to the anterior lobe by complex system of blood vessels.
- The function of hypothalamus
  - i) control secretion of hormone.
  - ii) Hunger & thirst.
  - iii) Body temp.
  - iv) Autonomic nervous system
  - v) emotional seek<sup>n</sup> & thoughts.
  - vi) biological clock & cardiac system.

Brain mostly manages  
spinal cord

## Function of Cerebrum

- Intelligence centre
- Thinking, reasoning.
- sensory perception like touch, pain, temp, heat, hearing, smell.
- control voluntary function in muscle contraction

- Cerebrum is divided into two parts as their function area

- i} Sensory area
- ii} Motor area

## Mid-Brain

- M.O.B situated around the cerebrum & cerebellum area above the pons.

## → Optic lobe

- optic nerve situated in optic lobe cranial nerve no. II
- The function of optic lobe is to vision.

## → Auditory lobe

- A.O.L is a centre for hearing the cranial nerve for auditory nerve is

## # Hind - Brain

- It is situated backside. & it is divided into three types cerebellum, pons, medulla.

### → cerebellum

- It is situated behind the pons & immediately below the posterior position of the cerebellum.
- The cerebellum consists grey matter & white matter in deep (inside it).
- The function of cerebellum co-ordinates with muscle contraction by voluntary action & maintain body posture.
- It co-ordinates activities associated with maintenance of balance & equilibrium posture of the body.

### → Pons

- It is situated in front of cerebellum below the mid brain & above the medulla oblongata.
- It consists a nerve fibres, forming a bridge b/w two hemisphere of cerebellum (left & right).

- pons varoli is the respiratory centre by which synchronicity of respiration is controlled

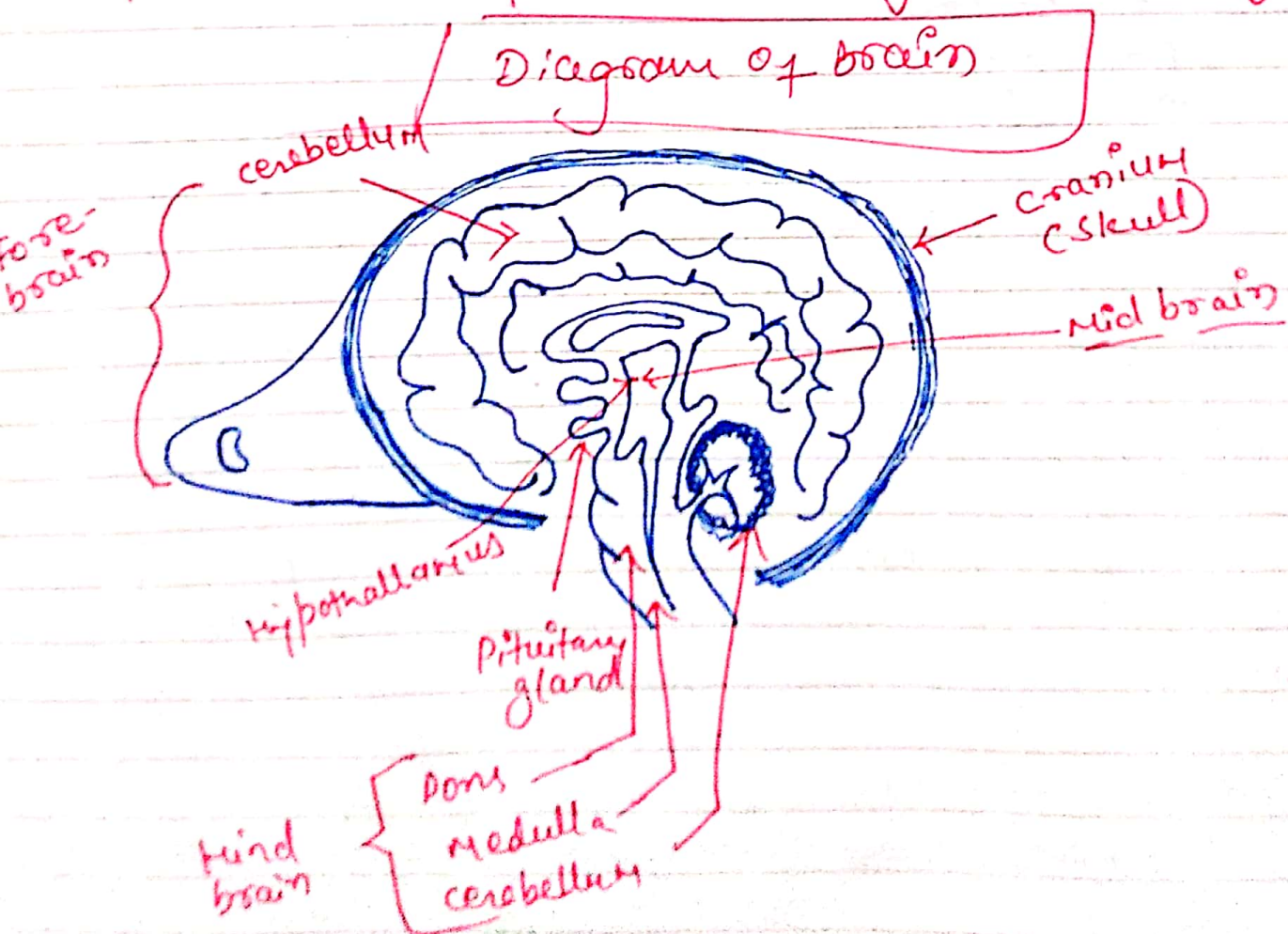
→ Medulla oblongata

- is situated at the extent from the pons varoli & it continues with spinal cord.

- It is pyramidal shape structure.

- The following vital activities are associated with "autonomic reflex activity" like, cardiac centre, respiratory centre, voluntary muscle contract.

- Reflex centre for vomiting or sneezing



→ Sensory Area

- The sensory cortex is a section of the cerebral cortex which is responsible for receiving & interpreting sensory information from different parts of the body.

→ Motor Area

- Responsible for planning, controlling & executing voluntary movement.

Moving towards the superior ...


# Cerebrum

- Frontal
- Temporal
- Parietal
- Occipital

↳ is a part of forebrain. [is the front part of brain]

↳ Thalamus / Hypothalamy

↳ pituitary gland. It releases hormone which alter a lot of functions of our body. It is secreted from anterior pituitary.



Right hemisphere

Corpus callosum (which is made up of white matter)



Left hemisphere

Myelin sheath is present at all parts.

- It is the largest part of brain.
- It is divided by a deep cleft the longitudinal cerebral into two hemispheres i.e. right & left.
- Each hemisphere contains one ventricle.
- Left ventricle → present in right hemisphere ⇒ vice versa
- The both hemispheres are connected by a mass of white matter (myelinated region of nerve fiber) called as corpus callosum. It separates the two hemispheres —




Superficial part of cerebrum is composed of nerve cell or grey matter forming cerebral cortex & deepest layer consist of nerve fiber or white matter.

- There are many folds present in cerebellum to exposed area called as gyri. These are separated from sulci (fissures) . These are convolution.  
 → deep projection.


- These convolution inc. the surface area of brain.

# The Afferent & Efferent Unlaine b/w the two hemisphere of brain.

→ Association tract :

- connect different part of cerebral hemisphere by extending from one gyrus (single unit of gyrus)  from one ~~side~~ divide two hemisphere, left/right.

→ Commissural tract :

- These tract are the corresponding area of two hemisphere the largest commissural  → corpus callosum is the largest tract of commissural.


→ Projection tract :

- They connect the cerebral cortex with grey matter of lower part of brain & the spinal cord.

## # Function of cerebral cortex :

- Mental activities involve in memory, intelligence, sense of responsibility,  
→ Thinking, moral sense & learning are the centre of higher attribute.
- sensory ~~perception~~ <sup>analysis</sup> perception, perception of pain, temp, touch, hearing, taste & smell, sight.
- It is the initiation centre of control of voluntary functions of skeletal muscles

## • functional area of cerebral cortex :



## → Motor area :

- It coordinate with CNS & directly act on skeletal muscles.
- The location of motor area is in frontal lobe.
- The motor area of cerebrum control the feet & those in lowest part of body.

→ Sensory area

- It controls the involuntary functions & from sensory to CNS.
- These areas are highly sensible for pain temp. touch, awareness of body movement & the position of joints.
- These sensory areas receive <sup>message</sup> from left side of body & transfer the signal to the right hemisphere or vice versa.